

PJN

ISSN 1680-5194

PAKISTAN JOURNAL OF
NUTRITION

ANSI*net*

308 Lasani Town, Sargodha Road, Faisalabad - Pakistan
Mob: +92 300 3008585, Fax: +92 41 8815544
E-mail: editorpjn@gmail.com



Research Article

The Effect of the Aqueous Extract of *Origanum vulgare* on the Postnatal Development of the Rat Prostate

Abdullah G. Al Kushi

Department of Anatomy, College of Medicine, Umm Al-Qura University, Makkah, Kingdom of Saudi Arabia

Abstract

Background and Objective: Oregano has a light green color, a strong aromatic odor and a pleasant bitter taste. Oregano is widely used as an herb and in traditional medicine. The effects of oregano on female and male reproductive main organs were studied in sexually mature rats but the prostate was not examined; thus, the aim of our study was to elucidate the postnatal effect of oregano on the prostate. **Materials and Methods:** One-day-old 80 male albino rats were used in this study. The rats were assigned to two main groups, the *Origanum vulgare*-treated and control groups. *Origanum vulgare* was orally administered to male rats at 80 mg kg⁻¹ day⁻¹ as a bolus by an orogastric tube. The animals in the control group in this study received the same volume of deionized water. The relative masses of organs, including the prostate, were measured at the end of the treatment. **Results:** A significant increase ($p < 0.01$) in prostate weight was detected in the treated group. Histopathological assessment was performed on the prostate and prostate samples were processed for light microscopic examination. A histopathological analysis of the prostatic tissue from treated rats showed normal cellular architecture with the 80 mg kg⁻¹ body weight treatment. **Conclusion:** Our results showed that the cells were regularly shaped; thus, this herb caused no disorders at this time of application and only insignificantly decreased the testosterone level. Therefore, additional attention should be directed towards understanding the effect of the persistent application of oregano during the prenatal period.

Key words: Albino rats, histopathological analysis, *Origanum vulgare*, prostate, radioimmune assays, traditional medicine

Received: May 21, 2019

Accepted: July 03, 2019

Published: September 15, 2019

Citation: Abdullah G. Al Kushi, 2019. The Effect of the aqueous extract of *Origanum vulgare* on the postnatal development of the rat prostate. Pak. J. Nutr., 18: 930-935.

Corresponding Author: Abdullah G. Al Kushi, Department of Anatomy, College of Medicine, Umm Al-Qura University, Makkah, Kingdom of Saudi Arabia

Copyright: © 2019 Abdullah G. Al Kushi. This is an open access article distributed under the terms of the creative commons attribution License, which permits unrestricted use, distribution and reproduction in any medium, provided the original author and source are credited.

Competing Interest: The author has declared that no competing interest exists.

Data Availability: All relevant data are within the paper and its supporting information files.

INTRODUCTION

Natural products and their active principles as sources for new drug discovery and treatment of diseases have attracted attention in recent years. Their medicinal use has been gradually increasing in developed countries. *Origanum vulgare* is one of the most widely used species of the Lamiaceae family and is a common condiment for various foods and beverages¹.

Some studies have provided evidence that oregano improves growth in growth-retarded animals. Oregano is primarily used to treat nausea but it is also used as an anti-inflammatory agent, pain remedy, warming remedy and antioxidant herb². *Origanum vulgare* is commonly known as wild marjoram and winter sweet³.

Origanum vulgare is widely used in traditional medicine as a diuretic and antispasmodic agent and has other medicinal uses, such as stimulant, expectorant, antibacterial, anticancer, anti-inflammatory, antioxidant and laxative effects⁴.

Origanum vulgare is rich in caracole, a chemical used as a painkiller, to reduce blood cholesterol and glucose levels, to suppress tumor activity and to treat respiratory and digestive disorders in menstrual defects⁵⁻⁷.

Origanum vulgare has antioxidant effects and protects against cell damage induced by oxidation⁸⁻¹⁰.

Origanum vulgare has substances with actions similar to progesterone, promoting normal development¹¹. The toxic effect of some drugs on the embryo in early pregnancy and their potential to induce a miscarriage is known¹². Some medicinal plants have toxic effects on mouse embryos^{13,14}. The effect of an aqueous extract of *O. vulgare* on early development in pregnant mice has been established¹⁵.

Treatment with oregano essential oil had a clear effect on developing fetuses at the highest dose used and this treatment did not cause any maternal toxicity or change the general behavior or the development of adult rats^{16,17}.

The overall goal of this study was to shed light on the event that takes place in prostate of male albino rats after chronic exposure to *O. vulgare* by studying postnatal development.

MATERIALS AND METHODS

Animals and husbandry: Experiments were performed in compliance with the guidelines of the Institute of Laboratory Animal Resources, Commission on Life Sciences, National Research Council and approved by the Ethical Committee for Research on Animals (ECRA) of Umm Alqura University, Saudi Arabia¹⁸.

The *O. vulgare* plant was purchased from Seekam Company and identified by taxonomist. The aerial part of the plant material was cleaned to remove adulterants and soaked for three days in aqueous methanol (30:70) with occasional shaking at room temperature. Filtration was carried out using a muslin cloth and then Whatman qualitative grade 1 filter paper. This procedure was repeated twice and then, all the filtrates obtained were combined and concentrated on a rotary evaporator (RE-111, Buchi, Flawil, Switzerland) with a B-700 recirculation chiller and a water bath model 461 at 40°C, yielding approximately 12% crude extract^{19,20}.

Dosing: The treated group was exposed to 80 mg kg⁻¹ body weight of oregano via drinking water through Amber borosilicate glass water bottles fitted with a fluorocarbon septum containing stainless steel tubes and equipped with balls to minimize water dripping. The bottle systems were steam-cleaned twice weekly and the water bottles were individually filled daily²¹. Water consumption during a 24 h period was recorded. The dosing solutions were prepared based on average body weight and average daily water consumption²².

The study group included 80 1-day-old male albino rats. The rats were assigned to two main groups, the *O. vulgare*-treated and control groups and each main group was divided into the following 4 subgroups: the first group was sacrificed at the 10-day stage; the second group was sacrificed at the 20-day stage; the third at the 30th day stage and the adult group was sacrificed on the 50th day.

Radioimmune assays: Serum LH, FSH and testosterone concentrations were measured by radioimmune assays in male rats from birth to 50 days of age.

RESULTS

The rat prostate was studied during development with histological approaches. The prostate gland of the rat consists of two symmetrical pear-shaped lobes located ventral to the urinary bladder and its neck and a single dorsolateral lobe located along the lateral and posterior aspects of the urethra. The stroma of the gland is composed of delicate connective tissue.

The individual acini are surrounded by fibrous tissue containing a thin layer of circular smooth muscle fibers. The elastic fibers are confined to the outer part of the capsule. The gland is formed of acini that vary in size and shape. The ventral prostate gland is merocrine, while the dorsolateral prostate is both holocrine and apocrine. The acini are lined with tall

columnar, cuboidal or flat cells. The cells containing basophilic granules are in the supranuclear region (Fig. 1 and 2) and all of these phenotypes were similar in the adult untreated and oregano-treated groups (Fig. 3).

Prostate development: The prostate gland (ventral and dorsolateral) appears as multiple solid cords extending from the urogenital sinus. Each cord is surrounded by mesenchymal tissue.

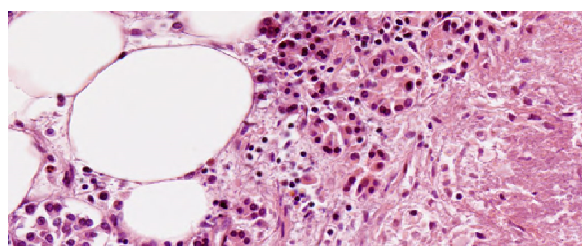


Fig. 1: A photomicrograph of a section of ventral prostate of a control adult rat Showing inner fatty layer of capsule and the lining columnar epithelium ($\times 500$)

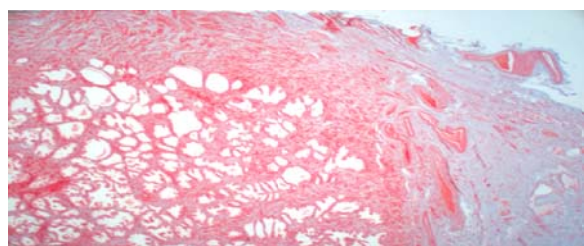


Fig. 2: A photomicrograph of a section of ventral prostate of a control adult rat stained with H and E Showing the duct and the lining low columnar epithelium ($\times 200$)

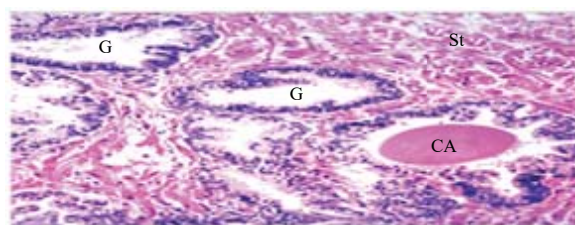


Fig. 3: A photomicrograph of a section of ventral prostate of an oregano treated group adult rat Showing polysaccharides in the secretion and the lining columnar epithelium ($\times 500$) (G: Gland, CA: canalization, St: stroma)

At the 10-day stage, the mesenchymal tissue is differentiated into delicate connective tissue, while that the tissue surrounding the cords becomes fibrous. Canalization begins in the solid cords of the ventral prostate. The connective tissue was positive for Periodic Acid Schiff (P.A.S) staining (Fig. 4) and all of these phenotypes were similar in the adult untreated and oregano-treated groups (Fig. 5).

At the 20-day stage, canalization is completed in the ventral lobe, while it begins in the dorsolateral prostate.

The acini are lined with columnar epithelium. The connective tissue around the individual acini becomes thin (Fig. 6) and all of these phenotypes were similar in the adult untreated and oregano-treated groups (Fig. 7).

At the 30-day stage, canalization is completed in the dorsolateral prostate gland and secretion begins from the ventral lobe. The acini are lined with columnar to flat epithelium.

The connective tissue around the individual acini becomes thin (Fig. 8) and all of these phenotypes were similar in the adult untreated and oregano-treated groups (Fig. 9 and 10).

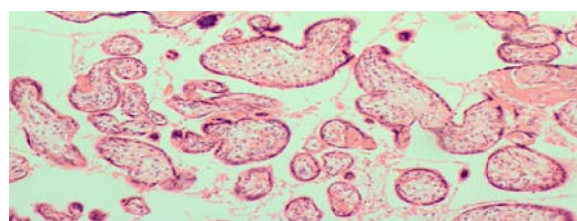


Fig. 4: Photomicrograph of transverse section of the rat (control), postnatal day10, showing Canalization begins in the solid cords of the ventral prostate (Hx and E) ($\times 200$)

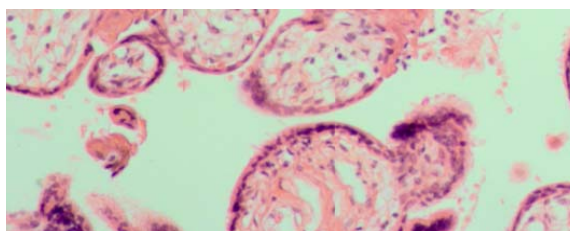


Fig. 5: Photomicrograph of transverse section of the rat (oregano treated group), postnatal day10, showing Canalization begins in the solid cords of the ventral prostate (Hx and E) ($\times 300$). (rate cell death in treated is high)

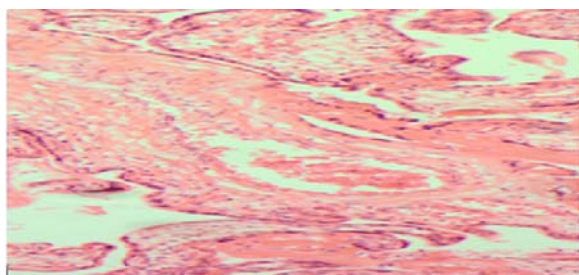


Fig. 6: Photomicrograph of transverse section of the rat (control), postnatal day-20, showing canalization is completed in the ventral lobe (Hx and E) ($\times 500$)

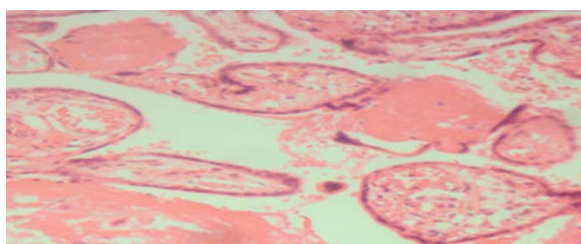


Fig. 7: Photomicrograph of transverse section of the rat (oregano treated group), postnatal day-20, showing canalization begins in the dorsolateral prostate. (Hx and E) ($\times 400$)

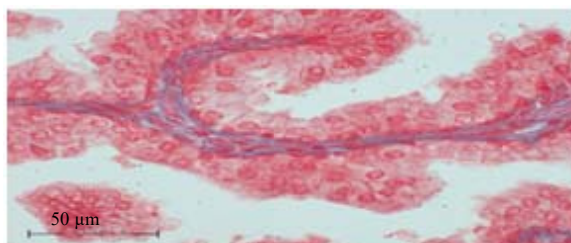


Fig. 8: Photomicrograph of transverse section of the rat (control), postnatal day-30, showing canalization is completed in the dorsolateral prostate (Hx and E). ($\times 500$)

Histopathological study

Light microscopy: The relative organ masses (mg/100 g body mass) of rats increased significantly ($p < 0.01$) after *in vivo* treatment with oregano and the relative masses of the ventral and dorsolateral gland prostate were also impacted.

Radioimmune assays: The levels of FSH increased significantly during the first 5 days of postnatal life. An abrupt decrease in FSH concentrations occurred during this

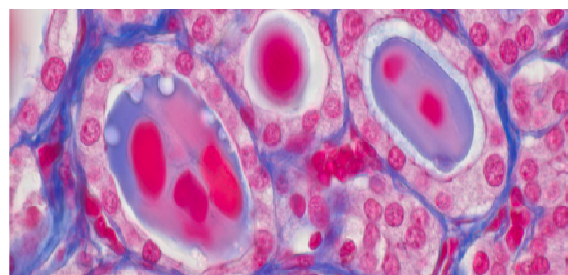


Fig. 9: Photomicrograph of transverse section of the rat (oregano treated group), postnatal 30th and showing secretion polysaccharides in the secretion begins from ventral lobe and the lining cuboidal epithelium (PAS $\times 500$)

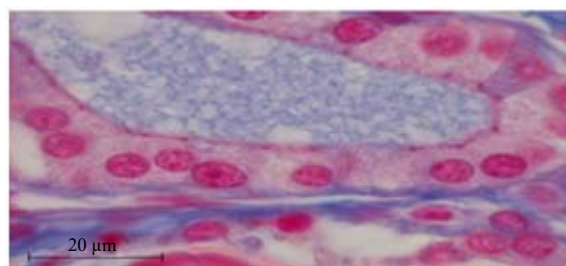


Fig. 10: Photomicrograph of transverse section of the rat (oregano treated group), postnatal 30th and showing connective tissue around the individual acini becomes thin with basophilic secretion in the secretion and the lining cuboidal epithelium (HE $\times 500$)

period, from 800 ng mL^{-1} on day 1- 300 ng mL^{-1} on day 6. This decline extended to the 8th day in the oregano-treated group.

Subsequently, FSH levels widely fluctuated until approximately day 40 in the control group and extended to the 50th day in the oregano-treated group, when a secondary peak of FSH was observed. Thereafter, FSH levels declined to the levels observed in adult rats. During the first 30 days of postnatal life, LH and testosterone values appeared to be inversely related and an LH peak and a nadir of testosterone levels were observed between days 6 and 14, a time corresponding to the regression of the fetal generation of interstitial cells. A parallel increase in LH and testosterone levels occurred from day 30 to sexual maturity and corresponded to the development of the adult generation of interstitial cells. All hormone levels, except the LH level, in all stages significantly decreased in the treated group compared with the control group (Table 1).

Weight monitoring during a treatment period provides an indication of the animal's health status, which can provide important information regarding the absence of toxicity.

Table 1: Serum LH, FSH and testosterone levels (ng mL⁻¹ serum) in male rats from birth to 50 days of age

Age of rats (days)	FSH		LH		Testosterone	
	Treated	Control	Treated	Control	Treated	Control
0-5	720±54	798±42	4.32±0.3	3.33±0.4	0.72±0.15	0.92±0.11
9-11	289±21	299±31	4.44±0.2	3.76±0.3	0.59±0.19	0.68±0.16
19-21	215±37	262±53	3.44±0.3	2.75±0.4	0.35±0.5	0.47±0.7
29-31	392±22	419±19	0.79±0.2	0.68±0.1	0.77±0.1	0.80±0.2
50	193±20	219±55	3.86±0.5	3.24±0.2	1.10±0.3	1.22±0.3

Values are given as the mean±S.E.M. (n)

Weight analysis revealed no difference in weight gain between the two groups. This result supports the hypothesis that no systemic toxicity occurred in treated animals during the treatment period.

DISCUSSION

The use of some medicinal plants has toxic effects on mothers during pregnancy, leading to complications and effecting embryonic development. It is important to know whether *O. vulgare* has an effect on reproductive development, either altering development or promoting normal development, not inducing maternal toxicity and not changing the general behavior and development of adult rats^{11,12,16,17}. We concluded that there is no toxic effect of *O. vulgare* on prostate structure.

Moreover, ultrastructurally, there was no difference between the normal and *O. vulgare*-treated groups and there was no sign of cell death²³. This finding indicates that the aqueous extract of *O. vulgare* did not have toxic effects on the postnatal development of the prostate, protects against cell damage due to its antioxidant effects and promotes normal development⁸⁻¹¹.

Postnatal development of the ventral prostate: The decrease in FSH levels appears to coincide with the first release of mature spermatozoa from the germinal epithelium in the testis. The mesenchymal tissue stroma of the ventral prostate in 10-day-old rats is differentiated into delicate connective tissue that contains thick fibrous connective tissue and some circular smooth muscle fibrous around the individual acini. Elastic fibers are confined to the outer part of the prostatic capsule.

At the 20-day stage, the thick fibrous connective tissue around the acini becomes thin. These findings confirm previous results in rats²⁴. Price²⁴, however, did not describe any elastic fibers. Additionally, the prostate gland of newly born rats appears as multiple solid cords of cells that canalize on the 10 postnatal day. These findings confirm observations of Price²⁴. Canalization, however, is subject to interspecies

differentiation and the acinar epithelial lining of the ventral prostate changes from cuboidal to columnar cells occurs on the 20th day. The gland at this stage is similar to the gland in adults, except in the absence of secretion, which starts to appear on the 30th day²⁵.

Postnatal development of the posterolateral prostate: In the present study, the dorsolateral prostate appeared as multiple solid cords of cells arising from the urogenital sinus. The cords were surrounded with mesenchymal tissue that differentiated at the 10-day stage into delicate connective tissue. However, the tissue that closely surrounds the individual cords became fibrous in nature.

Canalization begins on the 20th day of life, converting the solid cords into acini that are lined by a simple columnar epithelium, Canalization is completed by the 30th day when some of the acini start to show signs of apocrine secretion, as confirmed by Gunm and Galud²⁶.

As the spermatogenic process in rats ends within a few days after birth, it is of interest to note that serum FSH levels were markedly elevated during the 1st week of life. The elevated levels of FSH may be involved in the initiation of the spermatogenic process involving division of gonocytes to form spermatogonia. Alternatively, these high levels may be related to the hypothalamo-hypophyseal unit and catecholamine fluorescence in the median eminence of the hypothalamus does not intensify until day 5²⁷⁻³⁰.

CONCLUSION

The use of *O. vulgare* showed no structural effect on prostate cells; treated prostate cells were regularly shaped. Thus, this herb does not cause disorders at this time of application and causes only an insignificant decrease in the testosterone level.

SIGNIFICANCE STATEMENT

This study discovered *O. vulgare* may can be beneficial for prostate development in rats. This study will help to give

insight into the effect of *O. vulgare* on prostate cell structure and testosterone levels in postnatal rats. Thus, a new safe use of *O. vulgare* as an antioxidant was proposed.

REFERENCES

- Gilani, A.H. and Atta-ur-Rahman, 2005. Trends in ethnopharmacology. J. Ethnopharmacol., 100: 43-49.
- Williamson, E.M., 2001. Synergy and other interactions in phytomedicines. Phytomedicine, 8: 401-409.
- Usmanghani, K., A. Saeed and M.T. Alam, 1997. Indusyunic Medicine. University of Karachi Press, Karachi, pp: 420-421.
- Duke, J.A., 2002. Handbook of Medicinal Herbs. 2nd Edn., CRC Press, Boca Raton, pp: 609-610.
- Bakkali, F., S. Averbeck, D. Averbeck and M. Idaomar, 2008. Biological effects of essential oils-A review. Food Chem. Toxicol., 46: 446-475.
- Goze, I., A. Cetin and A. Goze, 2010. Investigation of effects of essential oils of *Origanum minutiflorum* O Schwarz PH Davis and *Cyclotrichium niveum* (Labiatae) plants on angiogenesis in shell-less chick embryo culture. Afr. J. Biotechnol., 9: 2156-2160.
- Verma, R.S., L. Rahman, R.K. Verma, C.S. Chanotiya and A. Chauhan *et al.*, 2010. Changes in the essential oil content and composition of *Origanum vulgare* L. during annual growth from Kumaon Himalaya. Curr. Sci., 98: 1010-1012.
- Yoshino, K., N. Higashi and K. Koga, 2006. Antioxidant and antiinflammatory activities of oregano extract. J. Health Sci., 52: 169-173.
- Jaloszynski, K., A. Figiel and A. Wojdylo, 2008. Drying kinetics and antioxidant activity of oregano. Acta Agrophys., 11: 81-90.
- Lamaison, J.L., C. Petitjean-Freytet and A. Carnat, 1990. Rosmarinic acid, total hydroxycinnamic derivatives and antioxidant activity of Apiaceae, Boraginaceae and Lamiceae medicinals. Ann. Pharm. Fr., 48: 103-108, (In French)..
- Arcila-Lozano, C.C., G. Loarca-Piña, S. Lecona-Urbe and E.G. de Mejía, 2004. El orégano: Propiedades, composición y actividad biológica de sus componentes. Archivos Latinoamericanos Nutrición, 54: 100-111.
- Stanley, F. and C. Bower, 1986. Teratogenic drugs in pregnancy. Med. J. Aust., 145: 596-599.
- Benavides, V., O. D'Arrigo and J. Pino, 2001. Efectos embriotóxicos de picrosia longifolia don (ASTERACEAE). Rev. Peru de Biol., 8: 80-82.
- Gutierrez-Pajares, J.L., L. Zúñiga and J. Pino, 2003. *Ruta graveolens* aqueous extract retards mouse preimplantation embryo development. Reprod. Toxicol., 17: 667-672.
- Benavides, V., G. Trujillo, G. D'arrigo, U. Paredes and J. Pino, 2000. Evaluación toxicológica preliminar de *Ruta graveolens*, *Origanum vulgare*, y *Persea Americana* sobre embriones pre implantacionales de ratón. Rev. Peru. Biol., 7: 87-89.
- Hollenbach, C.B., R.S. Bing, R. Stedile, F.P. da Silva Mello and T.L. Schuch *et al.*, 2015. Reproductive toxicity assessment of *Origanum vulgare* essential oil on male Wistar rats. Acta Scient. Vet., 43: 1-7.
- Hollenbach, C.B., R. Stedile, F.P.D.S. Mello, R.S. Bing and P.P.D. Rosa *et al.*, 2017. Pre-and postnatal evaluation of offspring rats exposed to *Origanum vulgare* essential oil during mating, gestation and lactation. Ciência Rural, Vol. 47, No. 1. 10.1590/0103-8478cr20150299
- Edeoga, H.O., D.E. Okwu and B.O. Mbaebie, 2005. Phytochemical constituents of some Nigerian medicinal plants. Afr. J. Biotechnol., 4: 685-688.
- Lemhadri, A., N.A. Zeggwagh, M. Maghrani, H. Jouad and M. Eddouks, 2004. Anti-hyperglycaemic activity of the aqueous extract of *Origanum vulgare* growing wild in Tafilalet region. J. Ethnopharmacol., 92: 251-256.
- Srihari, T., M. Sengottuvelan and N. Nalini, 2008. Dose-dependent effect of oregano (*Origanum vulgare* L.) on lipid peroxidation and antioxidant status in 1,2 dimethylhydrazine induced rat colon carcinogenesis. J. Pharmacy Pharmacol., 60: 787-794.
- Armitage, P., 1955. Tests for linear trends in proportions and frequencies. Biometrics, 11: 375-386.
- Cochran, W.G., 1954. Some methods for strengthening the common χ^2 tests. Biometrics, 10: 417-451.
- Stuckhardt, J.L. and S.M. Poppe, 1984. Fresh visceral examination of rat and rabbit fetuses used in teratogenicity testing. Teratog. Carcinog. Mutagen., 4: 181-188.
- Price, D., 1936. Normal development of the prostate and seminal vesicles of the rat with a study of experimental postnatal modifications. Am. J. Anat., 60: 79-127.
- Ortiz, E., 1953. The effects of castration on the reproductive system of the golden hamster. Anatomical Rec., 117: 65-91.
- Gunn, S.A. and T.C. Gould, 1957. A correlative anatomical and functional study of the dorsolateral prostate of the rat. Anatomical Rec., 128: 41-53.
- Smith, G.C. and R.W. Simpson, 1970. Monoamine fluorescence in the median eminence of foetal, neonatal and adult rats. Zeitschrift Zellforschung Mikroskopische Anatomie, 104: 541-556.
- Miyachi, Y., E. Nieschlag and M.B. Lipsett, 1973. The secretion of gonadotropins and testosterone by the neonatal male rat. Endocrinology, 92: 1-5.
- Sahin, F., M. Gulluce, D. Daferera, A. Sokmen and M. Sokmen *et al.*, 2004. Biological activities of the essential oils and methanol extract of *Origanum vulgare* ssp. vulgare in the Eastern Anatolia region of Turkey. Food Control, 15: 549-557.
- Sharma, N. and D. Jacob, 2002. Assessment of reversible contraceptive efficacy of methanol extract of *Mentha arvensis* L. leaves in male albino mice. J. Ethnopharmacol., 80: 9-13.