

PJN

ISSN 1680-5194

PAKISTAN JOURNAL OF
NUTRITION

ANSI*net*

308 Lasani Town, Sargodha Road, Faisalabad - Pakistan
Mob: +92 300 3008585, Fax: +92 41 8815544
E-mail: editorpjn@gmail.com

Acute Toxicity of *Euphorbia helioscopia* in Rats

S.I. AL-Sultan and Yehia A. Hussein

Departments of Public Health and Animal Husbandry, Clinical Studies, College of Veterinary Medicine and Animal Resources, King Faisal University, P.O. Box 11647, Al-Ahsa 31982, Saudi Arabia

Abstract: Fifty two Wistar albino rats of both sexes were used for determination of the LD50 and some toxicological studies of the active principles of *Euphorbia helioscopia* (sun spurge). The oral LD50 was 1211.7 mg/kg. b.wt. of crude ethyl alcohol extracts under our environmental conditions. The symptoms appear on the intoxicated animals were included increase activity and irritability, salivation, itching the nose and mouth on the cage floor, and diarrhea. The animals were tried to make tunnels under the bed and they were reluctant to stand at the cage corners. Finally the animals closed its eyes and become calm. The animals administered high dose were died after a latent period (3 hours) and some of the animals in other groups were died within 24 hours. Concerning the haematological changes, there were no significant changes of PCV, Hb concentration, RBCs count, while there were significant increase of WBCs, and monocytes. Also there were highly significant increase and decrease of neutrophils and lymphocytes respectively. The biochemical changes were revealed significant increase in creatinine, urea, uric acid, AST, ALP, cholesterol, T. protein and globulin. PM examination showed alveolar hemorrhages, proliferation of Kupffer cells, necrosis infiltrated by lymphocytes in lung, liver and spleen. Hyaline deposits and pinkish staining proteinaceous deposits were seen in Bowman's space of some glomeruli. It is concluded that *E. helioscopia* was a moderate toxic materials and must be avoided to introduce in the animal feed.

Key words: *Euphorbia helioscopia*, LD50, pathology, rat

Introduction

The family *Euphorbiaceae* is well - represented in Saudi Arabia. In general it consists of two groups of plants. One group which includes the genus *Euphorbia* contains milky juice in special tissue in their bodies. The other group with plants like *Ricinus* or *chrozophora* does not contain milky juice but have a watery sap. Fifteen genera of this family have been recorded from Saudi Arabia. The largest genus is the genus *euphorbia*. All species of this genus is the very broad Arabic names, the lubbaina because of their milky latex most often present under some pressure in the lattici-ferous tissue in the plant body. The latex of these plants contains various biochemical compounds, some of which are poisonous to various degrees or of medicinal importance or of commercial use. The latex usually protects these plants from browsing animals because of its bitterness or poisonous nature. The *euphorbia* species in Saudi Arabia fall into three or four broad categories e.g. the low annual or perennial herbs, the semi succulent or cactus-like succulent shrubs and the succulent or non-succulent trees. The succulent tree *Euphorbias* are often given the name candelabra trees. Sikula (1981) recorded that *Cypress spurge* (*Euphorbia cyparissias* L.), Marsh spurge (*E. palustris* L.), Broad spurge (*E. platyphyllos* L.), sun spurge (*E. helioscopia* L.), wood spurge (*E. amygdaloides* L.), Hungarian spurge (*E. esula* L.), petty spurge (*E. peplus* L.) and dwarf spurge (*E. exigua* L.) were produced a poisonous white latex. The latex was contained euphorbic acid,

euphrbine, proteins, tannins, volatile oils, alkaloids, resins, and other substances. Drying did not remove its toxicity. Euphorbic acid anhydride was the main toxic component of the latex, and had a locally irritant effect on the skin and on the epithelium of the alimentary, sometimes diarrhea with blood in the faeces, feeble heart-beat, and depression of the central nervous system. Poisoning may occur in almost all animal species.

Clarke *et al.* (1981) reported that many of the spurges were contained an acrid, vesicant juice, and some contained cyanogenetic glycosides. In Europe and North America cases of poisoning in children and animals occurred from time to time but were of rare occurrence. In Australia, however, certain species (For example, *E. clutoides*, *E. boophthoma* and *E. drummondii*) were very dangerous to stock (Gardner and Bennetts, 1953). The South African *E. mauritanica* has been shown to be poisonous to sheep, giving rise to groaning, salivation, ruminal paresis, tachycardia and continues shivering. The animals were reluctant to stand, and move with a stiff and unsteady gait (Terblanche *et al.*, 1966).

Sun spurge (*Euphorbia helioscopia*) is a networked herb occasionally found in Saudi Arabia. The latex contains a strong irritant that causes burning and a swelling in animals that ingest it. Sheep were poisoned and a human child died after ingesting the plant. This plant can cause irritation to livestock that ingestion it (Cooper and Johanson, 1984).

The herbaceous *Euphorbia* species are part of the landscape in Saudi Arabia and are also weeds of agricultural areas e.g. *E. Granulate*, *E. grossheimii*, *E. helioscopia*, *E. hirta*, *E. retusa*, *E. schimperiana*, etc. (Chaudhary and Al-Jawaid, 1999).

The present study was undertaken to investigate the following aspects.

- 1- The toxicity of *E. helioscopia* in rats.
- 2- To study the clinicopathological profile in animals.

Materials and Methods

Plant: The whole parts of *Euphorbia helioscopia* (leaves, stem, fruits, and roots) were freshly collected from the around area of the College of Veterinary Medicine and Animal Resources, King Faisal University. Approximately 1 kg of dried plant material were ground and extracted with 80% ethanol by shaking and percolation for 24 hours at room temperature. The extract was centrifuged at 1000 rpm for 10 minutes. The solvent of supernatant liquid was removed completely by evaporation under vacuum in rotary evaporator at 40°C. Prior to administration; the residue was dissolved in distilled water at suitable concentration. This extract was used for oral administration of rats.

Rats: Fifty two wistar albino rats of both sexes were used in this investigation. These animals were apparently healthy and weighed 120-150 g. Rats were housed in hygienic fiber glass cages. They were obtained from the animal house of the College of Veterinary Medicine and Animal Resources, King Faisal University. Animals were fed on commercial pellets. These rats were used for acute and sub chronic experimental toxicity studies. The rats were allowed free access to tap water and feed throughout the experimental.

Study, all animals were observed daily for signs of toxicity. Body weight was monitored at the commencement of the study and then at weekly intervals. All animals were killed at the termination of the experiment.

Determination of the LD50 in rats: According to the method of Weil (1952) for determination of the dose of LD50, exploratory trials were performed in five groups each of 2 rats of both sexes. Alcoholic extract was administered orally in doses of 500, 600, 700, 800, and 900, mg / kg bwt in the five groups to find the smallest toxic dose to start with. The dose 500 mg/kg bwt which was the least dose to cause signs of toxicity was multiplied by a constant factor (1.5) for each succeeding group of rats.

Five groups of rats were used (6 each) 1st, 2nd, 3rd and 4th were given 700, 1050, 1575 and 2362.5 mg/kg bwt alcoholic extract respectively. The fifth group was kept as control. Mortality rate was recorded after 24 hours.

Sub chronic toxicity: 12 adult rats were allocated into 2 equal groups (6 rats each). The 1st was daily administered orally with 1/5 LD50 corresponding to 242.340 mg/kg bwt aqueous solution of *E. helioscopia* alcoholic extract. The 2nd group was administered distilled water orally as a control. All rats were kept under observation throughout the experiment. All animals were killed after 4 weeks.

Haematological picture: Haematological picture including packed cell volume (PCV), haemoglobin concentration (Hb), erythrocytic count (RBCs), total and differential leukocytic count were determined according to the methods served by Schalm (1975), and MacGregor *et al.* (1940).

Biochemical changes: To study the effect of *E. helioscopia* alcoholic extract in rats on serum constituents, blood samples from each animal were taken in clean sterile tubes and left till clotting occurred. Serum was collected after centrifugation at 3,000 rpm for fifteen minutes. Serum was kept at -20°C until used. Chemical analysis was carried out on serum, to assess the state of the liver and kidney. This included: serum glutamic oxalacetic transaminase (GOT), serum glutamic pyruvic transaminase (GPT), alkaline phosphatase (ALP), total protein, albumin, globulin, cholesterol, uric acid, creatinine and urea nitrogen. Analysis was performed according to the set description of Bayer Corporation, SERA PAK (1997), with the aid of AMES QUIK-LAB chemistry analyzer, Miles Inc., Germany.

Histopathological studies: All the sacrificed rats were necropsied. Specimens were collected from different organs and fixed in 10% neutral buffer formalin. Paraffin sections (6-8 microns) were prepared and stained with Harris haematoxylin and eosin (Carleton and Dr Ury, 1967) for microscopic examination.

Statistical analysis: Statistical analysis of the obtained data was performed according to Snedecor and Cochran (1980).

Results

Clinical signs: The clinical signs were included increase activity and irritability, salivation, itching the nose and mouth on the cage floor, and diarrhea. The animals were tried to make tunnels under the bed and they were reluctant to stand at the cage corners. Finally the animals closed its eyes and become calm. The animals administered high dose were died after a latent period (3 hours) and some of the animals in other groups were died within 24 hours.

LD 50 determination:

Haematological picture: The results obtained revealed

that there were no significant results including PCV%, HB%, RBCs, eosinophilis% and basophilis%; while there were increase significant changes in WBcs count and monocytes ($P=0.05$), highly significant increase of neutrophilis and highly significant decrease of lymphocytes ($P=0.001$) as shown in Table 2.

Biochemical changes: Significant differences ($P=0.05$) in the values of creatinine, total protein, globulin and cholesterol and ($P=0.001$) in the values of AST, ALP, uric acid, and urea, were observed between the test and control groups (Table, 3); no significant differences in GOT and albumin.

Pathological studies: The results obtained revealed that: Treated group showed:

Stomach: No significant lesion observed. Mucosal and submucosal proliferation of lymphocytes was seen at fundic region

Small Intestine: Active goblet cells with appearance of many lymphocyte-like cells in the cytoplasm of villous and crypts cells, which appeared to be actively dividing. Hypercellularity of lamina propria observed with numerous lymphocytes and argentoffin cells.

Lungs Showed hyperaemia, emphysema and increased interstitial tissue at places associated with peribronchial cellular reaction composed mainly of lymphocytes and numerous eosinophilis. Peribronchial lymphoid hyperplasia was prominent in some sections while others showed alveolar haemorrhages (Fig. 1). Foci of necrosis were noticed infiltrated by lymphocytes, neutrophilis and eosinophilis. Perivascular edema and perivascular ring haemorrhages were also seen (Fig. 2).

Liver Proliferation of Kuppfer cells. Focal foci of hepatocyte necrosis infiltrated by lymphocytes. Degenerative hepatocytes with cytoplasmic acidophilia and pyknotic nuclei were often seen (Fig. 3).

Kidney Congestion of glomerular capillaries with some tubules showing hyaline deposits. Pinkish staining proteinaceous deposits were seen in the Bowmans space of some glomeruli.

Spleen Splenic follicles showed pale centers exhibiting some necrotic lymphocytic cells and proliferation of reticular cells (Fig. 4).

Heart Showed no significant findings.

Testes Showed normal structure of an actively functioning testes.

Brain Congestion, glial proliferations in some areas (Fig. 5).

Table 1: LD 50 determination in rats.

Groups / group	No. of animals	Dose mg/kg body weight	No. of deaths	% of deaths
1	6	700	-	0
2	6	1050	2	33.33
3	6	1575	5	83.33
4	6	2362.5	6	100
5	6	Control	-	0

$\log m = \log Da + d (F + 1)$

Where

Log m = the log of LD50

Log Da = the log of the lowest of the four dosage level used

D = the logarithm of the constant ratio between dosage levels.

F = A constant factor obtained from Weil's tables.

Log m = $\log 700 + \log 1.5 (0.33333 + 1)$

= $2.845098 + 0.1760912 (1.33333)$

= $2.845098 + 0.2347877$

= 3.0798857

Anti log m = 1211.7

L D 50 = 1211.7 mg / kg bwt.

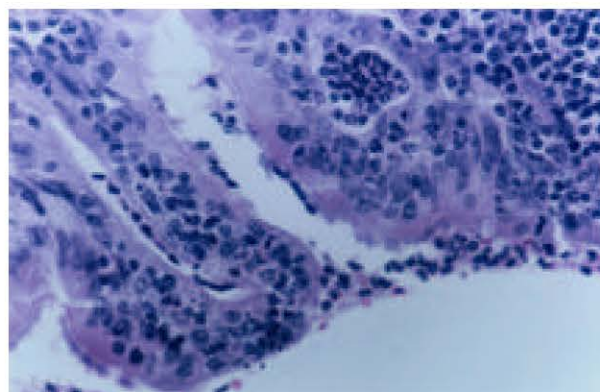


Fig. 1: Lung; damaged bronchial wall infiltrated by mononuclear and polymorphous cells. HE X 100

Discussion

Search of the available literature revealed no investigation concerning the toxicity of the active principle of the poisonous plant *E. helioscopia* in the laboratory animals.

Our results concerning the LD50 of the active principle of *E. helioscopia* revealed that the dose of The LD50 was 1211.7 mg/kg.bwt. for rats under environmental conditions. There are no available literatures concerning LD50 of any *Euphorbia* species on animals.

The symptoms of toxicity were partial in parallel to that mentioned in the toxicity by different species of genus *Euphorbia* by Kingsbury (1964), Frohne and Pfander (1983), Cooper and Johnson (1984), and Fuller and McClintock (1988) *E. cyparissias*, *E. helioscopia*, *E. esula*,

Table 2: Haematological picture of rats administered 1/10 LD50 of the active principles of *E. helioscopia* for 4 weeks

PCV%	39.17±0.43	39.00±1.14
Hb g/dl	11.00±0.20	11.85±1.08
RBCs 10/cm	8.05±0.17	8.08±1.02
WBCs 10 /cm	8.56±0.59	12.88±0.37*
Neutrophils	19.20±2.19	38.50±6.25**
Lymphocytes	67.00±2.36**	32.50±6.45
Monocytes	4.63±0.70	19.50±6.56*
Eosinophils	9.17±1.05	9.25±4.92

* Significant (P = 0.05). ** Highly significant (P = 0.001)

Table 3: Blood chemistry of rats treated orally by 1/5 LD50 *E. helioscopia* alcoholic extract for 4 weeks

	Control (mean±SE)	Treated (mean±SE)
Creatine mg/dl	0.82±0.31	1.05±0.11*
Urea mg/dl	38.0±1.08	67.33±5.96**
Uric acid mg/dl	1.38±0.60	3.98±0.57**
ALT u/L	42.5±0.85	37.33±5.35
AST u/L	128.0±0.71	240.17±9.40**
ALP u/L	66.38±3.65	198.2±34.5**
Cholesterol mg/dl	65.33±1.40	75.17±6.39*
Total Protein g/dl	6.40±0.19	8.67±0.68*
Albumin g/dl	3.53±0.40	3.87±0.18
Globulin g/dl	2.87±0.08	4.8±0.542*

* Significant (P = 0.05). ** Highly significant (P = 0.001).

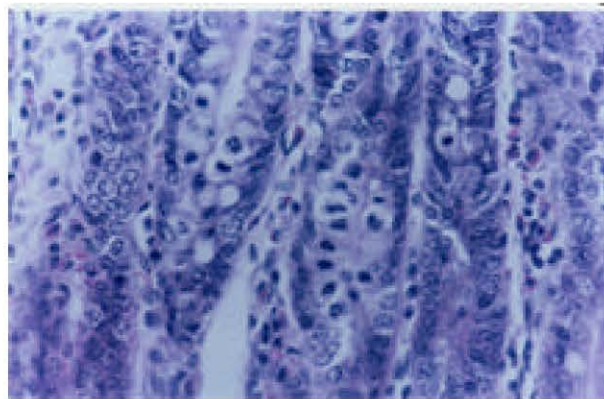


Fig. 2: Lung; showing areas of emphysema and thickened interstitial tissue. Ring hemorrhage around blood vessel and presence of neutrophils in lumen of bronchiole. HE X 40.

and *E. lathyris* in human being, respectively, Sikula (1981) in most animal species, and Kingsbury (1964) and Terblanche *et al.* (1966) in sheep, Frohne and Pfander (1983) and Krobergng (1990) *E. cyparissias* and *E. esula* in cattle. They were mentioned that the symptoms were salivation, vomition, diarrhea, burning of the mouth, esophagus, and stomach, narrowing of the eye pupil, growing, ruminal paresis, tachycardia,

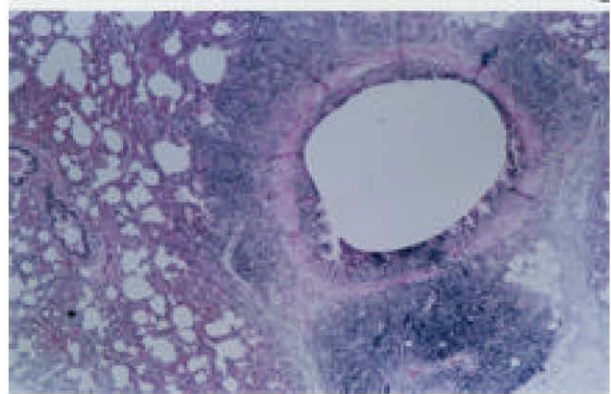


Fig. 3: Liver; focal hepatocyte degeneration with slight mononuclear cells infiltration. HE X 100

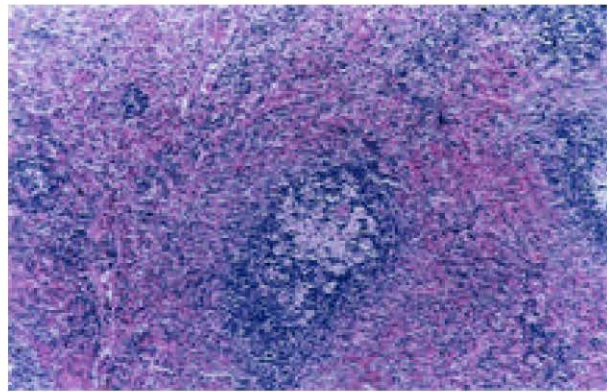


Fig 4: Spleen; showing lymphoid follicle showing central lymphoid depletion and presence of reticular cells. HE X 100

continues shivering,. The animals were reluctant to stand, and move with a stiff and unsteady gait.

Concerning the blood picture there were no any significant changes including PCV%, Hb%, RBCs count, eosinophils%, and basophils%. While there were significant increase of WBCs count, and monocytes%, highly significant increase of neutrophils and highly significant decrease of lymphocytes. Leukocytosis and neutrophils were probably a response to tissue degeneration and necrosis. The decrease lymphocyte count could be attributed to the direct effect of the active principles of *E. helioscopia* on lymphocytes which are referred to antibody formatting cells.

In this study, there was a significant increase in the level of serum enzymes, namely, GOT, and ALP, after feeding of alcoholic extract of the aerial parts of *E. helioscopia* to rats. The rise in GPT and ALP activities may be related to the liver injury as observed in histopathology. The activity of GPT, as compared to GOT, is relatively higher in the liver than in other tissues. Therefore, the measurement of GPT has been found to be useful in the diagnosis of

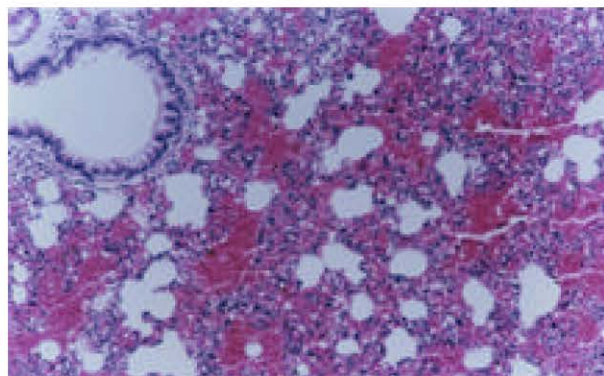


Fig. 5: Brain; neuronal degeneration characterized by rounding of cells cytoplasmic acidophilia and nuclear degeneration . HE X 100.

hepatic disease and damage in animals (Wroblewski and La Due, 1956; Howard and Matsumoto, 1997). The ALP showed a significant increase, which was marked at the end of the experimental period as compared with control. The elevation in ALP activity could be attributed to hepatobiliary affections (Coles, 1974).

Total protein was increased associated with increase in albumin fraction. This can be attributed to the hepatic degenerative changes, which were confirmed clinically and histopathologically. Coles (1974) mentioned that any alteration in total protein was considered of significance both diagnostically and prognostically and those alterations revealed the presence of some pathological conditions.

The level of urea, uric acid and creatinine of the intoxicated rats was increased significantly. This increase may indicate renal function impairment due to *E. helioscopia* toxicosis. This may be supported by the occurrence of renal lesions. Significant increase in the level of creatinine may occur in renal damage and excessive muscular catabolism and during pregnancy in young human or loss of skeletal muscle caused by trauma, atrophy, necrosis or starvation (Coles, 1974; Kelly, 1984; Metwalli, 1987; Hassieb *et al.*, 1988; El-Grieb, 1990). Uric acid and cholesterol were increased significantly in treated rats. In human cholesterol may increase in cases of biliary cirrhosis and in nephritic syndrome and increased level of uric acid may be associated with defect in renal excretion.

On the other hand, there were no any available literatures concerning histopathological studies of *Euphorbia* species toxicity in animals. The histopathological lesions obtained were included mucosal and submucosal proliferation of lymphocytes was seen at fundic region of stomach. Alveolar haemorrhages and foci of necrosis were noticed infiltrated by lymphocytes, neutrophils and eosinophils at lung. Proliferation of Kupffer cells and focal foci of

hepatocytes necrosis infiltrated by lymphocytes in the liver. Some tubules of kidney showed hyaline deposits. Pinkish staining proteinaceous deposits were seen in Bowman's space of some glomeruli. Splenic follicles showed pale center exhibiting some necrotic lymphocytic cells and proliferation of reticular cells.

References

- Bayer Corporation, Sera Pak, 1997. Reagent kits for *in vitro* diagnostic, USA.
- Caesar, A.J., N.E. Rees, N.R. Spencer and P.C. Quimby 1993. Characterization of Rhizoctonia Spp. Causing disease of leafy spurge in Northern Great Plains. Plant Disease, 77: 681-684.
- Carleton, M.A. and R.A.B. Drury, 1967. Carleton's histological technique. 3rd ed., Oxford University Press, New York, Toronto.
- Chaudhary, S.A. and A.A. Al-Jawaid, 1999. Vegetation of the Kingdom of Saudi Arabia. National Agriculture and Water Research Center, Ministry of Agriculture and Water, Kingdom of Saudi Arabia.
- Clarke, M.L., D.G. Harvey and D.J. Humphrey, 1981. Veterinary Toxicology. 2nd ed. Bailliere Tindall, London, pp: 219.
- Coffey, T., 1993. The History and Folklore of North American Wild Flowers. Facts on File.
- Coles, E., 1974. Veterinary clinical pathology. 2nd ed. Philadelphia, London.
- Cooper, M.R. and A.W. Johnson, 1984. Poisonous plants in Britain and their effects on animals and man. Her Majesty's Stationery Office, London, England, 305 pp.
- El-Grieb, S.A., 1990. Metabolic disorders among sheep reared in Behera Governorate. M.V.Sc. Thesis, Fac. Vet. Med., Alexandria University.
- Foster, S. and J.A. Duke, 1990. A field Guide to Medicinal plants- Eastern and Central N. America. Houghton Mifflin Co.
- Frohne, D. and H.J. Pfander, 1983. A Color Atlas of Poisonous Plants – Wolfe Publishing Ltd. London, England, pp: 291.
- Fuller, T.C. and E. Mc Clintock, 1988. Poisonous Plants of California. Univ. California Press, Berkeley, Calif, USA, 432 PP.
- Gardner, C.A. and H.W. Bennetts, 1953. J. Dep. Agric., W. Aust., 2: 527.
- Grieve, 1984. A Modern Herbal. Penguin.
- Hassieb, M.M., A.A. El-Swak, F.R. Ali and Y.A. Hussein, 1988. Phenylmercuric chloride toxicosis in rats. Alexandria. J. Vet. Sci., 4: 509-521.
- Howard, E.B. and G. Matsumoto, 1997. Laboratory procedures. In: Animal health technology (formerly animal hospital technology). 2nd ed., Catcott. E.J. (ed.). American Veterinary Publications, Inc., USA, pp: 227-258.

Sultan and Hussein: Acute Toxicity of *Euphorbia helioscopia* in Rats

- Kelly, W.R., 1984. In: Veterinar and clinical diagnosis, 2nd ed. W.R. Kelly (ed.). Baillier Trindall, London, pp: 260-300.
- Kingsbury, J.M., 1964. Poisonous plant of the United States and Canada. Prentice – Hall Inc., Englewood Cliffs, N. J. USA, 626 PP.
- Krobergng, S., 1990. Leafy Spurge Toxicity to Cattle. Leafy Spurge News, 12: 7.
- MacGregor, R.G.S., W. Richards and G.L. Loh, 1940. The differential leukocytic count. J. Pathol. Bact., 51: 337.
- Matthews, V., 1994. The New Plants man. Volume 1 Royal Horticultural Society.
- Metwalli, A., 1987. Clinical laboratory investigation on a common disease manifestation among some farm animals. M.V.Sc. Thesis, Fac. Vet. Med., Alexandria University.
- Schalm, O., 1975. Veterinary Haematology. 3rd ed. Lea and Febiger, Philadelphia, USA.
- Sikula, J., 1981. Veterinary Toxicology (Developments in animal and veterinary science, 7). Ed. By Bartik, M. and Piskac, A. Elsevier Scientific Publishing Company New York.
- Snedecor, G. and W. Cochran, 1980. Statistical methods. 16th ed. The Iowa State University Press, Ames, Iowa, USA.
- Terblanche, M., T.F. Adelaar and A.M.S. Van Straten, 1966. J.S. Afr. Vet. Med. Ass. 37, 311.
- Weil, C., 1952. Tables for convenient calculation of median effective dose (LD50 or ED50) and instruction in their use. Biometrics 8, 249.
- Wroblewski, F. and J. La Due, 1956. Got in cardiac and hepatic disease. Proc. Soc. Biol. Med., 91: 569.